

Mechanochemical ablation: status and results

S Elias*, Y L Lam[†] and C H A Wittens^{†‡}

*Division of Cardiac, Thoracic and Vascular Surgery, Columbia University and Medical Center, NY, USA;

[†]Maastricht University Medical Centre, Department of Vascular Surgery, The Netherlands; [‡]Universitätsklinikum Aachen, Department of Vascular Surgery, Germany

Introduction

The evaluation of endovenous ablation in recent years has gravitated towards the search for a technique that is simpler, painless and eliminates tumescent anaesthesia. These newer techniques must still be as efficacious and safe as endothermal methods.

Over the last 10 years, numerous minimally invasive methods have been utilized to treat great and small saphenous vein incompetence.^{1,2} Most of these techniques involve percutaneous access, local anaesthesia, some form of ablation and short operative times with relatively good safety and efficacy. The endothermal technologies require the use of tumescent anaesthesia prior to energy delivery and a generator to produce either laser or radio-frequency energy. Results have improved and complications have decreased as these techniques and technologies have evolved.³ In the modern era of endothermal ablation (after 2006), efficacy rates of long-term closure are reported at levels well above 90%.^{4,5} However, these methods currently still require tumescent anaesthesia which can be a source of patient procedural discomfort; further, this portion of the procedure is the steepest part of the physician learning curve.

Recent reports have evaluated ultrasound-guided foam sclerotherapy of the great saphenous vein (GSV).⁶ While foam sclerotherapy does obviate the necessity for tumescent anaesthesia, efficacy rates are lower than endothermal ablation and reported complication rates are higher.^{7,8} Presently,

it cannot be stated that foam sclerotherapy is as efficacious as endothermal ablation.

Other methods such as cyanoacrylate glue⁹ or polidocanol endovenous microfoam¹⁰ also accomplish saphenous closure without using tumescence. Long-term results of these methods are not currently published and clinical trials are ongoing. However the concept of tumescent anaesthesia elimination is central to all of these as with mechanochemical ablation (MOCA).

A new mechanochemical device, (ClariVein[®]) was developed to minimize the negative aspects of both endothermal ablation and ultrasound-guided sclerotherapy (UGS) for the treatment of saphenous incompetence, while incorporating the benefits of each. The advantages of this hybrid system are standard percutaneous access, endovenous treatment, local anaesthesia only (no tumescent anaesthesia) and a shorter procedure time. Since this system does not use thermal energy, the potential for nerve damage is minimized. The negative aspects eliminated by the hybrid procedure are: the need for tumescence anaesthesia required for endothermal ablation and lower efficacy rates for UGS. The mechanochemical method achieves venous occlusion utilizing a wire rotating within the lumen of the vein at 3500 rpm which abrades (i.e. injures) the intima and causes venospasm to allow for better efficacy of the sclerosant. A liquid sclerosant (sodium tetradecyl sulphate [STS] or polidoconol [PLD]) is concomitantly infused through an opening close to the distal end of the catheter near the rotating wire. These two modalities, mechanical and chemical, achieve venous occlusion results equal to endothermal methods (Figures 1 and 2).

The entire device is for single use only and can be inserted through a 4 or 5 Fr sheath utilizing local insertion site anaesthesia only, without the need of tumescence anaesthesia. The system includes an infusion catheter, motor drive, stopcock and syringe (Figure 3).

Correspondence: S Elias MD FACS FACPh, Columbia Vein Programs, Division of Cardiac, Thoracic and Vascular Surgery, Columbia University and Medical Center, NY, USA, 350 Engle St, Englewood, NJ 07631, USA.
Email: veininnovations@aol.com

Accepted November 2012

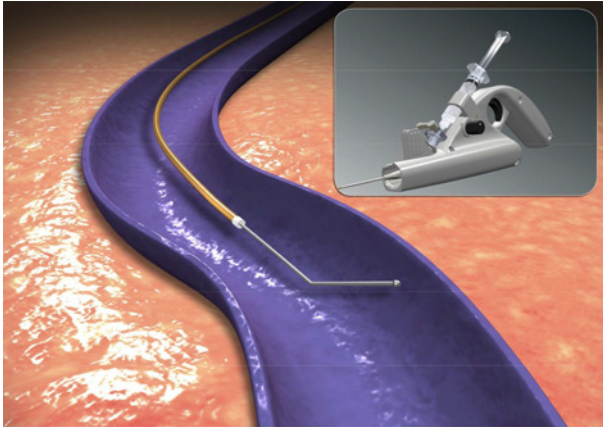


Figure 1 Device in vein

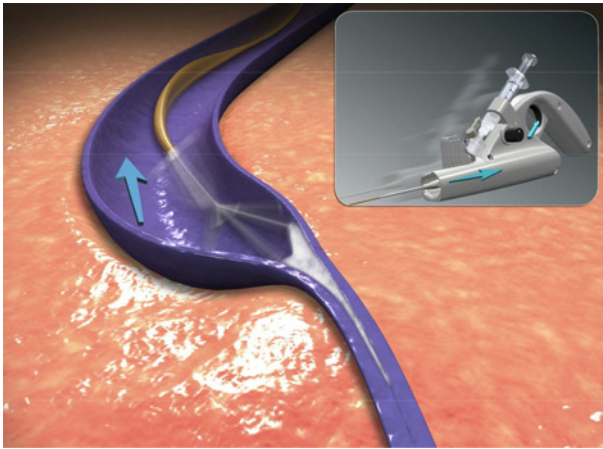


Figure 2 Mechanism of action

Materials and methods

ClariVein[®] is an infusion catheter system designed to introduce physician-specified medications intravenously with simultaneous mechanical agitation into a patient's peripheral vasculature. Infusion is through an opening at the distal end of the catheter. Fluid delivery is enhanced by the use of a rotating dispersion wire to mix the infused fluid in the target vein and onto the vessel wall, as well as, abrade the venous intima. The dispersion wire extends through the catheter lumen. It is connected to an interface Cartridge Unit for connection to the 9V DC battery motorized Handle Unit on the proximal end, which controls wire rotation. The Handle Unit also provides a grip and syringe holder to facilitate physician-controlled infusion. After purging with saline to insure a closed system and prior to drug infusion, the wire plus catheter sheath is inserted into the vein percutaneously. The catheter sheath is retracted to expose the wire




Figure 3 MOCA device

tip, of which is positioned 1–2 cm from the saphenofemoral (SFJ) junction or 1 cm proximal from the 'fascial' curve as the small saphenous vein (SSV) angles towards the saphenopopliteal junction (SPJ). The catheter motor is turned ON and with the wire rotating and with sclerosant infusing, the catheter is pulled down the vein at a rate of approximately 1–2 mm per second.

The wire that passes through the catheter is 304V stainless steel; the configuration of the dispersion tip has been optimized for mechanochemical vein ablation. The wire is steerable and therefore, will transverse most tortuous GSV segments.

Technique and results

The first in man clinical trial was initiated February 2009. The technique and results of this trial has been previously published.¹¹ The six-month closure rate was 96% (29/30 limbs). Subsequent follow-up at greater than two years still has a 96% closure occlusion rate (28/29 limbs)¹² VCSS scores improved as one expects from successful saphenous occlusion. No deep venous thrombosis (DVT) or nerve damage occurred. A feasibility and safety study by van Eekeren *et al.*¹³ utilizing PLD as sclerosant showed similar results in short-term follow up. No major adverse events occurred. A larger study by the same group of 224 GSVs had a six month occlusion rate of 96% as well.¹⁴

The above studies addressed the treatment of the GSV. A study by Boersma *et al.*¹⁵ that specifically looked at SSV treatment had good results as well. The one year occlusion rate in 50 patients was 94%. Venous Clinical Severity Score (VCSS) decreased significantly from 3 to 1. In this study as well no DVT or nerve injury were noted.

More importantly quality of life and post-treatment pain was studied by van Eekeren *et al.*¹⁶

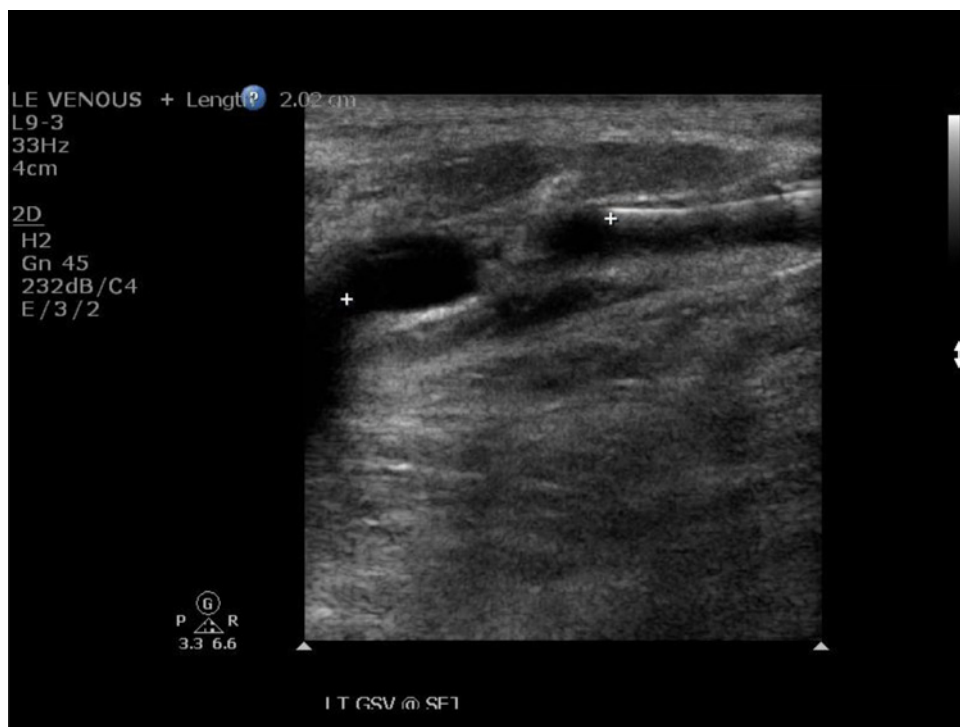

Figure 4 Position at SFJ

This was a retrospective, observational study comparing MOCA to radiofrequency ablation in 68 patients. Patients undergoing MOCA reported significantly less pain in the immediate 14-day post-operative period compared with RFA (4.8 versus 18.6 mm on a 100 mm visual analogue scale). This lower post-treatment pain score translated into an earlier return to normal activity (1.2 versus 2.8 days) and earlier return to work (3.3 versus 5.6 days). Both techniques yielded improved perceived change in health status and disease specific quality of life.

In all published series occlusion rates are usually reported at greater than 90%, at various postprocedure time intervals with minimal complications. Others have presented similar safety, efficacy and occlusion rates with improvement of quality of life.^{17,18} To date over 11,000 procedures have been completed worldwide.

Discussion

It appears from published studies that MOCA is safe and efficacious at various time intervals including as long as two-year follow up. It can be utilized for both GSV and SSV treatment with very low complication rates of DVT or nerve/skin injury. Most importantly patient quality-of-life improves and

there is minimal procedural and postprocedure pain.

The ability to attain successful vein occlusion without the need for tumescent anaesthesia is a further simplification of endovenous ablation. The elimination of this step is both advantageous to patient and physician. The procedure is shortened as well with an average time of 15 minutes. Elimination of tumescent infusion for endovenous ablation is the next logical step in the treatment of venous disease.

Since the original first in man study certain aspects of technique, clinical indications and *post op* duplex findings have emerged. Lessons learned include:

- (1) Regarding positioning at the SFJ or SPJ, this author now places the catheter 1 cm from the SFJ (Figure 4) or 1 cm below the 'fascial curve' as the SSV angles towards SPJ. The wire of the catheter is rotated without sclerosant infusion for the first centimeter at the start of pullback. This induces spasm in the vein and creates a vortex in the vessel. This action minimizes forward flow of liquid sclerosant into the deep venous system. At the 2 cm level sclerosant infusion is then started;
- (2) The technique is two handed. The hand closest to the insertion site does most of the pullback

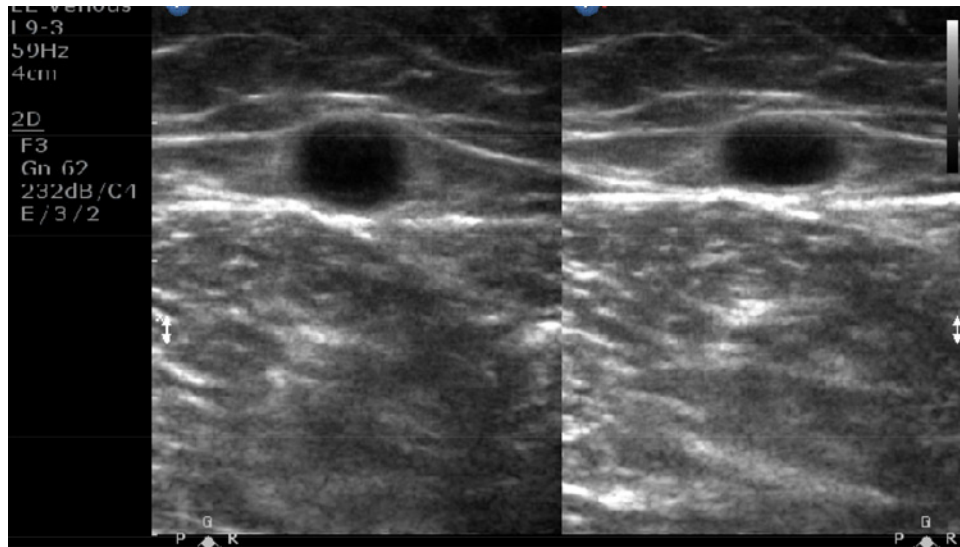


Figure 5 Post MOCA 1 month

and the hand on the motor unit controls the infusion of sclerosant. When the wire is rotating the catheter should be moving i.e. catheter on/catheter moving. One should not rotate the wire without pulling back because this can cause the wire to get caught on the vein wall if it is rotating when stationary. Initially, when first learning the technique, the tendency is for the operator is to pullback too fast and inject too slowly;

- (3) In terms of volume of sclerosant, all patients in the first in man trial received 12 cm³ of 1.5% STS regardless of the length or diameter of vein treated. Volume is now based on diameter and length and tends to be less than 12 cm³ (GSV 6–10 cm³, SSV 2–4 cm³). A table is available to minimize excess infusion;
- (4) The results using different concentrations of sclerosant have been variable. This author continues to use 1.5% STS for all procedures. Others have used polidocanol 1%, 2%, 3% and STS 1%. It appears that pullback rate is more important than concentration. If one maintains a pullback rate of 1.5 mm/seconds (1 cm/7 seconds) good results can be attained with various strengths. If one pulls back too fast occlusion rates can decrease;
- (5) Duplex ultrasound findings post-treatments are different than postendothermal ablation. Since the mechanism of action of MOCA is different one observes slower contraction. At one month the vein wall will appear 'sponge' like but will have no flow: one must access for flow with colour and not just use greyscale imaging (Figure 5).

- (6) Treatment of a GSV or SSV that is incompetent to the malleolar level can be safely accomplished as there is minimal risk of nerve damage. This is especially helpful in C5 or C6 patients. One may even pass the catheter retrograde to the malleolus under the ulcer. In particularly scarred skin or ulcerated skin it is difficult to place good tumescent anaesthesia so one may not be able to treat directly under the ulcer with endothermal ablation as one can with MOCA;
- (7) Branch varicosities can have liquid or foam sclerosant placed into them appropriately by directing the lumen of the catheter prior to saphenous treatment. This technique is helpful in C5 and C6 patients as well. The subcutaneous varicosities can be filled with ultrasound visualization to aid in ulcer healing;
- (8) Veins that may not be candidates for MOCA may include large diameter veins (>15 mm). Although this author has treated sizes to 20 mm. GSV or SSV with previous thrombophlebitis and recanalization also pose a challenge. Most times the catheter can be advanced to the SFJ/SPJ because it is a steerable wire essentially but when rotation starts the wire gets caught on the synechia within the vein lumen and a good treatment cannot be completed. Conversely, anticoagulated patients have had successful treatment.

Conclusion

The technique of mechanochemical ablation simplifies and shortens the procedure of endovenous

ablation. It eliminates the need for tumescent anaesthesia while attaining similar and acceptable efficacy rates as current endothermal techniques. Tumescentless ablation of the GSV or SSV is the next logical step in the evolution of endovenous ablation. Complications are rare and if necessary treatment can be done to the malleolar level without the risk of nerve or skin injury. Patient acceptance is high and there is minimal discomfort during or postprocedure. The learning curve is short (5–7 cases) if one already has experience with endothermal ablation. Mechanochemical ablation is another viable option for treatment of saphenous incompetence.

Funding

This research received no specific grant from any funding agency in the public, commercial, or not for-profit sectors.

Conflict of interest

Dr. Elias is a member of the Medical Advisory Board, Vascular Insights LLC.

References

- Merchant RF, DePalma RG, Kabnick LS. Endovascular obliteration of saphenous reflux: a multicenter study. *J Vascular Surg* 2002;**35**:1280–92
- Cavezzi A, Frullini A, Ricci S, Tessari L. Treatment of varicose veins by foam sclerotherapy: two clinical series. *Phlebology* 2002;**17**:13–8
- Almeida JL, Kaufman J, Gockeritz O, *et al.* Radiofrequency endovenous closureFAST versus laser ablation for the treatment of great saphenous reflux: a Multicenter Single-Blinded Randomized Study (RECOVERY). *J Vasc Interv Radiol* 2009;**20**:752–9
- Proebstle TM, Vago B, Alm J, *et al.* Treatment of the incompetent great saphenous vein by endovenous radiofrequency powered segmental thermal ablation: first clinical experience. *J Vasc Surg* 2008;**47**:151–6
- Brar R, Nordon IM, Hinchliffe RJ, *et al.* Surgical management of varicose veins: meta-analysis. *Vascular* 2010;**18**:205–20
- Blaise S, Bosson JL, Diamond JM. Ultrasound guided sclerotherapy of the great saphenous vein with 1% vs. 3% polidocanol foam: a multicentre double-blind randomized trial with 3-year follow-up. *Eur J Vasc Surg* 2010;**39**:774–8
- Hamel Desnos C, Ouvry P, Benigni JP, *et al.* Comparison of 1% and 3% polidocanol foam in ultrasound guided sclerotherapy of the great saphenous vein: a randomized double blind trial with 2 year follow-up. 'The 3/1 study'. *Eur J Vasc Surg* 2007;**34**:723–9
- Ceulen RPM, Bullens-Goessens Y, de Venne P-V, *et al.* Outcomes and side effects of duplex guided sclerotherapy in the treatment of great saphenous veins with 1% vs. 3% polidocanol foam: results of a randomized controlled trial with 1 year follow up. *Dermatol Surg* 2007;**33**:276–81
- Almeida J, Javier J, MacKay E, *et al.* Cyanoacrylate glue great saphenous vein ablation: preliminary 180 day follow up of a first in man study of a no compression, no local anesthesia technique. AVF Annual Meeting, Orlando, FL, February 2012
- Meyers KA, Roberts S. Evaluation of published reports of foam sclerotherapy: what do we know conclusively? *Phlebology* 2009;**24**:275–80
- Elias S, Raines JK. Mechanochemical tumescentless endovenousablation: final results of the initial clinical trial. *Phlebology* 2012;**27**:67–72
- Elias S. Mechanochemical ablation: MOCA. 2 year follow up, lessons learned. SVS Annual Meeting. Washington DC, June 2012
- van Ekeren RRJP, Boersma D, Elias S, *et al.* Endovenous mechanochemical ablation of great saphenous vein incompetence using ClariVein device: a safety study. *J Endovasc Ther* 2011;**18**:328–34
- DeVries JP, Reijnen M. Mechanochemical tumescentless endovenous ablation of the GSV and SSV with the ClariVein catheter. EVS Annual Meeting 2011
- Boersma D, van Eekeren RRJP, Werson DAB, *et al.* Mechanochemical endovenous ablation of small saphenous vein insufficiency using the ClariVein® device: One-year results of a prospective series. *EJVES* 2012; (Epub ahead of print) doi:10.1016/j.ejvs.2012.12.004
- van Eekeren RRJP, Boersma D, Konijn V, *et al.* Post-operative pain and early quality of life after radiofrequency ablation and mechanochemical endovenous ablation of incompetent great saphenous veins. *J Vasc Surg* 2012; (Epub ahead of print) doi:10.1016/j.jvs.2012.07.049
- Stenson K. ClariVein: A novel treatment for varicose veins. UIP Annual Meeting. Prague, 2011
- Bernstein RV. Mechanochemical (ClariVein) for defiant ulcers of the lower extremity. European Vascular Course 2012. Maastricht, Netherlands