

◆ CLINICAL INVESTIGATION ◆

Endovenous Mechanochemical Ablation of Great Saphenous Vein Incompetence Using the ClariVein Device: A Safety Study

Ramon R.J.P. van Eekeren, MD¹; Doeke Boersma, MD²; Steven Elias, MD³; Suzanne Holewijn, PhD¹; Debbie A.B. Werson²; Jean-Paul P.M. de Vries, MD, PhD²; and Michel M.J.P. Reijnen, MD, PhD¹

¹Department of Surgery, Rijnstate Hospital, Arnhem, The Netherlands. ²Department of Vascular Surgery, St. Antonius Hospital, Nieuwegein, The Netherlands. ³Division of Vascular Surgery Vein Programs, Columbia University, New York, New York, and Englewood Hospital, Englewood, New Jersey, USA.

Purpose: To evaluate the feasibility and safety of endovenous mechanochemical ablation (MOCA) for the treatment of great saphenous vein (GSV) incompetence.

Methods: The newly developed ClariVein device uses a technique that combines mechanical endothelial damage using a rotating wire with the infusion of a liquid sclerosant. Heating of the vein and tumescent anesthesia are not required; only local anesthesia is utilized at the insertion site. In a pilot study, 30 limbs in 25 patients (18 women; mean age 52 years) with GSV incompetence were treated with MOCA using polidocanol at 2 centers. Initial technical success, complications, patient satisfaction, and classification by venous clinical severity score (VCSS) were assessed 6 weeks after the treatment.

Results: Initial technical success of MOCA was 100%. There were no major adverse events. Minor complications consisted of 9 local ecchymoses at the puncture site and superficial phlebitis that resolved within a week in 4 limbs. Duplex ultrasonography at 6 weeks showed 26 (87%) of 30 veins were completely occluded; 3 veins showed partial recanalization in the proximal (n=2) and distal GSV. One patient had full segment recanalization and was successfully retreated. The VCSS significantly improved at 6 weeks (p<0.001). Patient satisfaction was high, with a median satisfaction of 8.8 on a 0–10 scale.

Conclusion: This study showed that endovenous MOCA, using polidocanol, is feasible and safe in the treatment of GSV incompetence. Larger studies with a prolonged follow-up are indicated to prove the efficacy of this technique in terms of obliteration rates.

J Endovasc Ther. 2011;18:328–334

Key words: varicose veins, venous incompetence, great saphenous vein, endovenous therapy, mechanical endothelial damage, sclerosant, polidocanol, endovenous ablation

Varicose veins cause symptoms varying from minor leg discomfort to chronic disabling venous ulceration. In a random sample of 1566 men and women aged between 18 and 64 years, the Edinburgh Vein Study showed

that 40% of the men and 32% of the women had varicose veins originating from saphenous vein reflux.¹

During the past decade, therapy for varicose veins has changed considerably. Thermal

Steven Elias was the principal investigator of the US clinical study sponsored by Vascular Insights LLC. The other authors have no commercial, proprietary, or financial interest in any products or companies described in this article.

Address for correspondence and reprints: Michel M.P.J. Reijnen, MD, PhD, Department of Surgery, Rijnstate Hospital, Wagnerlaan 55, 6815 AD Arnhem, The Netherlands. E-mail: mmpj.reijnen@gmail.com

endovenous modalities, including endovenous laser ablation and radiofrequency ablation, are highly effective for obliterating the

See commentary page 335

incompetent great saphenous vein (GSV).² Occlusion rates of over 90% are consistently reported in clinical trials, with low complication rates.^{3–5} Novel treatment modalities focus mainly on reducing surgical trauma, minimizing periprocedural and postprocedural pain, and improving cosmetic outcome.

Liquid sclerotherapy is an effective and minimally invasive procedure to treat reticular varicose veins and spider veins. However, disappointing results have been published using liquid sclerotherapy for the treatment of GSV incompetence. In a recent meta-analysis, Hamel-Desnos and Allaert⁶ found occlusion rates of only 39.5% treating GSV incompetence with liquid sclerotherapy after 1 year of follow-up. Foam sclerotherapy may be more effective, with occlusion rates of >76% after 1 year.⁶

Currently, tumescent anesthesia is required for all types of endothermal ablation, but thermal-related complications, such as prolonged pain, skin burn, and neuralgia, are described in the literature, although they are very rare.^{7,8} A new approach has recently been developed to induce occlusion by endovenous mechanical damage to the endothelial cells combined with infusion of a liquid sclerosant. This endovenous mechanochemical ablation (MOCA) technique does not require tumescent anesthesia, will not heat the vein or its surroundings, and is performed without an exogenous energy source. The present study evaluated the applicability and safety of MOCA in combination with polidocanol in an initial trial.

METHODS

Study Design

A protocol was constructed to evaluate endovenous MOCA in combination with polidocanol using the ClariVein catheter (Vascular Insights, Madison, CT, USA) at 2 Dutch hospitals. Ethical approval for the study was granted by the Committee on Research Involving Human Subjects at Arnhem-Nijmegen,

The Netherlands (reference 2009/071). Data were gathered prospectively in a computerized database.

Candidates for the study underwent color duplex ultrasonography by a certified vascular technologist. The CEAP class⁹ and venous clinical severity score¹⁰ were assigned by a skilled vascular surgeon. Reflux was defined as retrograde flow of >0.5 seconds after calf compression measured in an upright position. Eligibility criteria were age over 18 years, C2–C6 varicose veins, written informed consent, and primary GSV incompetence. Exclusion criteria included pregnancy and lactation, allergy or contraindication to the sclerosant, previous surgical treatment of varicose veins, history of deep venous thrombosis, the use of anticoagulants, severe tortuosity of the GSV, or GSV diameter <4 mm or >12 mm measured in the supine position.

Based on these criteria, 25 consecutive patients (18 women; mean age 52 years) with primary GSV incompetence in 30 limbs were enrolled in the study. Five patients had bilateral GSV insufficiency. Most treated limbs were classified as C2 using the CEAP classification (Table).

Study Device

The single-use, disposable ClariVein infusion catheter (Fig. 1A) contains a rotating dispersion wire that extends through its lumen; at the end of the wire is an angled tip that protrudes 2 cm. A small ball attached to the tip enhances ultrasonographic visibility and mechanically damages the endothelial layer as it rotates and disperses sclerosant into the bloodstream and onto the vessel wall (Fig. 1A). The catheter is connected to a 9V battery–motorized handle unit that controls wire rotation; a 5-mL syringe mounted on the handle delivers sclerosant. The catheter is inserted through a 4-F to 6-F micropuncture set positioned percutaneously via an 18-G intravenous access performed under ultrasound guidance.

Intervention

All procedures were performed under local anesthesia by a specialized team consisting of

TABLE
Baseline Characteristics and Operative Details for 25 Patients Undergoing
Endovenous Mechanochemical Ablation in 30 Limbs

Characteristics	
Men/women	7/18
Mean age, y	52.1±14.0
Body mass index, kg/m ²	26.9±4.6
VCSS	3.3±1.6
CEAP classification	
C2	18
C3	9
C4	3
C5–C6	0
Operative details	
Procedures performed at each center (Arnhem/Nieuwegein)	9/21
Duration of procedure, min	20±4.8
Vein diameter 2 cm below SFJ, mm	6.1±2.1
Vein diameter at puncture site, mm	4.8±1.25
Treated length, cm	40±6.6

Continuous data are presented as means ± standard deviation; categorical data are given as counts.
VCSS: venous clinical severity score, CEAP: clinical, etiology, anatomy, and pathophysiology, SFJ: saphenofemoral junction.

a vascular surgeon and vascular practitioner at each center. No tumescent anesthesia, sedation, or antibiotics were given. The patient was positioned supine with a cushion under the knee to enhance access to the medial part of the thigh. Under ultrasound

guidance, the GSV was accessed with an 18-G needle. Over a short guidewire, a 4-F microsheath was introduced and the guidewire was removed. The ClariVein catheter was positioned through the microsheath with the tip of the device 2 cm distal of the saphenofemoral

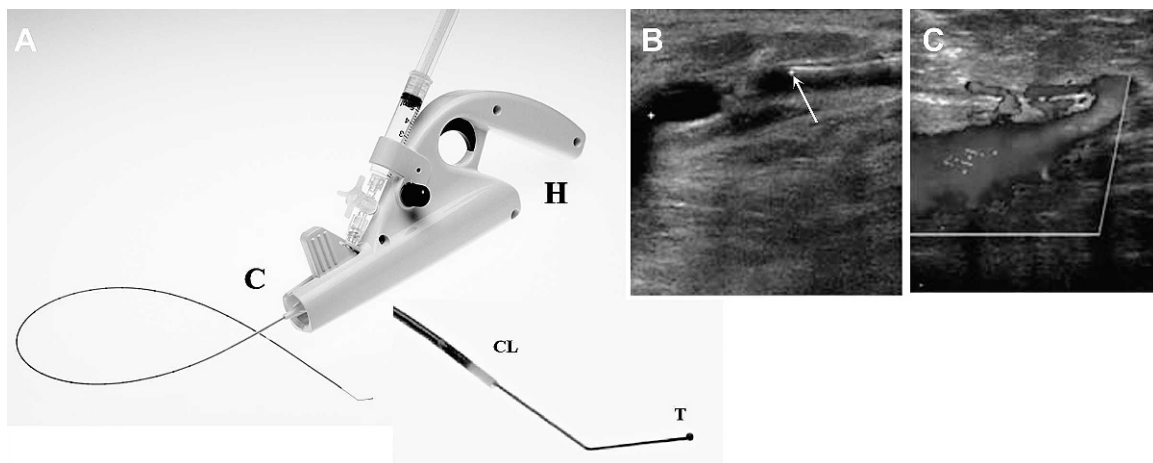


Figure 1 ♦ (A) The ClariVein device consists of a 9V battery–motorized handle unit (H) and cartridge unit (C) that contains the catheter with dispersion wire that extends through the catheter lumen (CL). The end of the wire has a dispersion tip (T) with a small ball attached that mechanically damages the endothelium. (B) Ultrasound guidance is used to position the dispersion tip (arrow) 2 cm below the saphenofemoral junction. (C) Duplex ultrasonography shows the saphenofemoral junction just after MOCA. The great saphenous vein is occluded.

junction (SFJ) under ultrasound guidance (Fig. 1B). The ClariVein catheter was then connected to the motorized handle unit, which unsheathed the distal end of the dispersion wire to expose the dispersion tip.

After the proper position of the dispersion tip was verified (the ball on the dispersion tip 2 cm distal of the SFJ), the wire was activated for a few seconds to induce spasm of the proximal vein. Then, the activated catheter with rotating tip was steadily withdrawn at 2 mm/s while simultaneously infusing a 1.5% polidocanol solution (Aetoxisklerol; Kreussler Pharma, Wiesbaden, Germany). The amount of liquid sclerosant was determined by the diameter of the varicose vein near the SFJ. During all procedures, the total dose of administered polidocanol was well below the maximum allowed dose. No concomitant phlebectomies were done.

Duplex ultrasonography was performed after the procedure to measure the length of the obliterated GSV and to confirm the patency of the deep venous system (Fig. 1C). The time taken to complete the procedure and length of the treated vein were noted. Patients were advised to walk for 20 minutes immediately after completion of the procedure. Patients were discharged with class 2 compression stockings (30–40 mm Hg) and advised to wear them for 24 hours continuously for 2 weeks.

Outcomes and Follow-up Protocol

The primary outcome measures were immediate occlusion, determined by duplex ultrasonography, and postprocedural complications. Secondary outcomes included patient satisfaction and postprocedural pain. Patients were asked to record the level of pain during treatment on a 100-mm visual analog scale. Following treatment, patients were asked to complete a diary card for 7 days to record the level of pain using the same scale. After 6 weeks, patients determined their satisfaction with the treatment using a 10-point scale. All patients were examined at 7 days and 6 weeks by a vascular surgeon; a duplex ultrasound evaluation was performed at the 6-week follow-up.

Statistical Analysis

Variables are presented as means \pm standard deviation if distributed parametrically or as the median and interquartile range (IQR, 25th to 75th percentiles) if nonparametrically distributed. Improvement in clinical condition measured using the venous clinical severity score was analyzed using the Wilcoxon signed rank test; $p < 0.05$ was considered significant. Statistical analysis was performed using SPSS software (version 15.0; SPSS Inc, Chicago, IL, USA).

RESULTS

During procedures that averaged 20 minutes (Table), the mean length of GSV treated was 40 cm. A mean volume of 6.8 ± 1.3 mL of polidocanol (15 mg/mL) was used. All treated veins showed occlusion on ultrasonography directly after MOCA. No major adverse events were observed. There was no deep venous thrombosis, nerve injury, skin necrosis, infection, or hyperpigmentation. Minor complications included localized ecchymosis at the puncture site in 9 patients and transient superficial phlebitis of distal tributaries in 4 patients.

At 6 weeks, no additional complications were observed clinically or detected with duplex ultrasonography. The GSV was completely obliterated in 26 (87%) of 30 veins, starting 2 cm distal from the SFJ. Two patients had partial recanalization of the proximal GSV 15 and 18 cm, respectively, from the SFJ; another patient had partial recanalization of the distal GSV. One total recanalization of the GSV was successfully treated in a redo procedure at 7 weeks after initial treatment. The mean vein diameter 2 cm below the SFJ in the 4 veins with recanalization was comparable with the completely obliterated veins (6.3 vs. 6.1 mm).

Patient Satisfaction and Outcome

During the procedure, the median maximal pain score was 4 (IQR 3–6) on a 10-point scale. The mean maximal pain measured on the first postprocedural day was 9 mm on a 100-mm scale. The score decreased to a mean of 2 mm

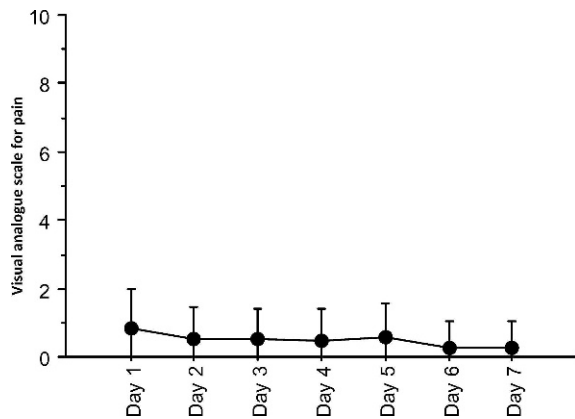


Figure 2 ♦ Visual analogue scale for pain within the first week after MOCA (n=12).

7 days after MOCA (Fig. 2). All 4 patients with superficial phlebitis had prolonged pain for >1 week.

After 6 weeks, median patient satisfaction of the treatment was 8.5 (IQR 8–9) on a 10-point scale. The median venous clinical severity score decreased significantly from 3.0 (IQR 2.0–4.75) to 1.0 (IQR 0.25–3.0) 6 weeks after treatment ($p < 0.001$). In the 3 patients with partial recanalization, the venous clinical severity score had decreased from 4.5 (IQR 3.5–5.5) to 2.0 (IQR 1.5–2.3) 6 weeks after treatment. The venous clinical severity score worsened from 5 to 11 in 1 patient with a superficial phlebitis.

DISCUSSION

Thermal endovenous modalities are highly effective for obliterating incompetent GSVs. A recent meta-analysis of the most common endovenous therapies in treating varicose veins showed 5-year success rates of 75.7% for surgical stripping, 73.5% for ultrasound-guided foam sclerotherapy, 79.9% for radiofrequency ablation, and 95.4% for endovenous laser ablation.² Though the surgical method of saphenofemoral ligation with stripping is still considered the gold standard, these results support the increasing popularity of endovenous therapy.

Endovenous mechanochemical ablation is a new technique in the endovenous toolbox. Its mechanism of action is a combination of mechanical damage of the endothelium and

scarring of the vein due to a liquid sclerosant. Animal experiments performed under the supervision of M. G. Tal of the Yale University School of Medicine have shown that the combination of mechanical damage with the chemical effect is crucial. Treatment with either the ClariVein catheter or with Sotradecol alone was not successful, while the combination of both produced permanent vein occlusion (unpublished data, personal communication). The ClariVein catheter's rotating tip causes spasm in the vein and mechanical damage to the endothelium, which increases the efficacy of the sclerosant that is dispersed over the endothelial layer. After successful treatment, the vein is obliterated and transformed into a fibrous cord.^{11,12}

The first results of MOCA using the ClariVein catheter and sodium tetradecyl sulfate (Sotradecol) were recently published.¹³ In that study, mechanochemical ablation of 30 GSV in 29 patients resulted in occlusion rates of 97% after 260 days. The only complication was thigh ecchymosis in 3 patients; no deep venous thrombosis, skin necrosis, or nerve injury occurred. Because Sotradecol is not approved in The Netherlands, we used polidocanol in our study, but our early outcomes were similar. Complete occlusion at 6 weeks was 87%. Only 3 patients had partial recanalization of the proximal or distal GSV, and 1 total recanalization was successfully retreated. A few patients had localized ecchymosis at the puncture site, which was probably caused by leakage of the sclerosant during pullback of the device. We also saw transient superficial phlebitis in 13% (4 limbs), which is higher than the current literature on endothermal modalities but lower than the incidences following the use of foam or liquid sclerotherapy (18% to 42%).^{14,15}

Most current minimally invasive endovenous modalities rely on conduction of heat to obliterate varicose veins, which has several disadvantages. Thermal ablative procedures require tumescent anesthesia to buffer the heat and prevent damage to the surrounding tissues, but tumescent anesthesia prolongs the procedural time. Moreover, nerve damage and prolonged pain are known, but rare, complications of endovenous laser ablation

with incidences of 0% to 7.3%^{7,8,16,17} and 2.6% to 7.9%, respectively.^{17,18} Skin burns were reported in early endovenous laser ablation experience.^{7,8}

MOCA is performed without tumescent anesthesia and requires only one injection with local anesthesia at the puncture site. There is no hardware to buy and maintain, and the technique can be performed on an outpatient basis, thereby further reducing procedure costs. However, studies are indicated to assess the cost-effectiveness of this technique. In our experience, MOCA is also probably faster than other endovenous techniques.

Patient satisfaction following MOCA is high, and the venous clinical severity score improved in all patients, except one with superficial phlebitis. Postprocedural pain scores were very low. Shepherd et al.¹⁹ described median postprocedural pain scores of 26 mm 3 days after endovenous laser; after radiofrequency ablation, the score was 15 mm at 3 days, while in our series, the pain score at day 3 was 5 mm. Randomized studies are required to prove reduced postoperative pain following MOCA compared to other techniques.

After 6 weeks, duplex ultrasonography showed recanalization in 4 treated veins in 30 limbs (3 partial and 1 complete). Thus, the anatomical success appears to be lower compared to thermal ablative techniques. Various factors may have contributed to this observation. First, the tip of the rotating wire was positioned 2 cm below the SFJ, which means that the tip of the catheter itself was located 4 cm distal to the SFJ and injection of the sclerosant also started 4 cm below the SFJ. Although the sclerosant was dispersed by the rotating wire, it might be possible that the first part of the target segment was treated only mechanically. These first results led us to treat the next series of patients by positioning the tip of the rotating wire 0.5 cm distal to the SFJ to prevent early recanalization of the proximal segment. Moreover, the concentration of sclerosant may have been insufficient; it has now been increased to 2% polidocanol for the proximal third, while the remaining vein is still treated with 1.5% polidocanol.

Finally, because all new techniques involve a learning curve to optimize results, this technique should be adopted when experience increases. Nevertheless, larger series with prolonged follow-up and randomized trials are clearly indicated, especially because most of the recanalizations with other techniques will occur during the first year after treatment.

Conclusion

The endovenous MOCA technique with the ClariVein device appears to be a safe and well-tolerated procedure, without the need for tumescent anesthesia and heating of the vein. Early results are promising, although studies with long-term follow-up and investigations evaluating the efficacy of different concentrations of sclerosant are indicated to define the role of MOCA.

REFERENCES

1. Evans CJ, Fowkes FG, Ruckley CV, et al. Prevalence of varicose veins and chronic venous insufficiency in men and women in the general population: Edinburgh Vein Study. *J Epidemiol Community Health*. 1999;53:149–153.
2. Van den Bos R, Arends L, Kockaert M, et al. Endovenous therapy of lower extremity varicosities: a meta-analysis. *J Vasc Surg*. 2009;49:230–239.
3. Ravi R, Trayler EA, Barrett DA, et al. Endovenous thermal ablation of superficial venous insufficiency of the lower extremity: single-center experience with 3000 limbs treated in a 7-year period. *J Endovasc Ther*. 2009;16:500–505.
4. Min RJ, Khilnani N, Zimmet SE. Endovenous laser treatment of saphenous vein reflux: long-term results. *J Vasc Interv Radiol*. 2003;14:991–996.
5. Darwood RJ, Theivacumar N, Dellagrammaticas D, et al. Randomized clinical trial comparing endovenous laser ablation with surgery for the treatment of primary great saphenous varicose veins. *Br J Surg*. 2008;95:294–301.
6. Hamel-Desnos C, Allaert FA. Liquid versus foam sclerotherapy. *Phlebology*. 2009;24:240–246.
7. Van den Bos RR, Neumann M, De Roos KP, et al. Endovenous laser ablation-induced complications: review of literature and new cases. *Dermatol Surg*. 2009;35:1206–1214.

8. Sichlau MJ, Ryu RK. Cutaneous thermal injury after endovenous laser ablation of the great saphenous vein. *J Vasc Interv Radiol*. 2004;15:865-867.
9. Kistner RL, Eklof B, Masuda EM. Diagnosis of chronic venous disease of the lower extremities: the "CEAP" classification. *Mayo Clin Proc*. 1996;71:338-345.
10. Rutherford RB, Padberg FT, Comerota AJ, et al. Venous severity scoring: an adjunct to venous outcome assessment. *J Vasc Surg*. 2000;31:1307-1312.
11. Mancini S, Lassueur F, Mariani F. Sclerosis of the great saphenous vein: an experimental study in humans of the sclerosing effect of iodo-iodide solution and polidodecane (histology and electron microscopy). *Phlebology*. 1991;44:461-468.
12. Martin DE, Goldman MP. A comparison of sclerosing agents: clinical and histologic effects of intravascular sodium tetradecyl sulfate and chromate glycerin in the dorsal rabbit ear vein. *J Dermatol Surg Oncol*. 1990;16:18-22.
13. Elias S, Raines JK. Mechanochemical tumescentless endovenous ablation: final results of the initial clinical trial. *Phlebology*. 2011; in press.
14. Uncu H. Sclerotherapy: a study comparing polidocanol in foam and liquid form. *Phlebology*. 2010;25:44-49.
15. Gonzalez-Zeh R, Armisen R, Barahona S. Endovenous laser and echo-guided foam ablation in great saphenous vein reflux: one-year follow-up results. *J Vasc Surg*. 2008;48:940-946.
16. Carradice D, Mazari FA, Mekako A, et al. Energy delivery during 810 nm endovenous laser ablation of varicose veins and post-procedural morbidity. *Eur J Vasc Endovasc Surg*. 2010;40:393-398.
17. Gandhi A, Froghi F, Shepherd AC, et al. A study of patient satisfaction following endothermal ablation for varicose veins. *Vasc Endovascular Surg*. 2010;44:274-278.
18. Zafarghandi MR, Akhlaghpour S, Mohammadi H, et al. Endovenous laser ablation in patients with varicose great saphenous vein incompetence and incompetent saphenofemoral junction: an ambulatory single center experience. *Vasc Endovascular Surg*. 2009;43:178-184.
19. Shepherd AC, Gohel MS, Lim CS, et al. Pain following 980-nm endovenous laser ablation and segmental radiofrequency ablation for varicose veins: a prospective observational study. *Vasc Endovascular Surg*. 2010;44:212-216.